

# Uterine Niche: A Pathology to Consider

## *Nicho Uterino: Uma Patologia a Considerar*

Francisca Mendes<sup>1\*</sup>, Joana Balseiro<sup>1</sup>, Filipa Alves<sup>2</sup>, Joana Sousa<sup>3</sup>, Joana Teles Sanches<sup>1</sup>, Joana Alves<sup>1</sup>

\*Autor Correspondente/Corresponding Author:

Francisca Mendes [fmpa91@gmail.com]

ORCID iD: 0000-0002-6787-7005

### ABSTRACT

Uterine niche is a recess located in the anterior wall of the uterine isthmus, over the cesarean section scar. This condition is often asymptomatic, but it can be associated with symptoms such as abnormal uterine bleeding, pelvic pain and secondary infertility. Endovaginal ultrasound is the first-line diagnostic method. Treatment includes hormonal methods or surgery, and surgical treatment seems to be the most effective in resolving symptoms. We describe the case of a 37-year-old woman, with an obstetric history of a pregnancy with cesarean delivery, who complained of pelvic pain and menstrual irregularity. An endovaginal ultrasound was requested, which reported the presence of a "... echogenic oval formation with well-defined limits measuring 28x17 mm in the topography of the cesarean scar." After a clinical discussion with a doctor specializing in Gynecology, the patient was referred to a hospital consultation in this specialty for investigation. The diagnosis of uterine niche was confirmed, and the treatment consisted of the placement of an intrauterine system.

**KEYWORDS:** Cesarean Section/adverse effects; Cicatrix; Uterine Diseases

1. USF BRIOSA, Coimbra, Portugal. 2. UCSP Montemor-o-Velho, Montemor-o-Velho, Portugal. 3. UCSP Soure, Granja do Ulmeiro, Portugal.

Recebido/Received: 2023/03/13 - Aceite/Accepted: 2023/08/22 - Publicado online/Published online: 2023/11/10

© Author(s) (or their employer(s)) and Gazeta Médica 2023. Re-use permitted under CC BY 4.0. No commercial re-use. © Autor (es) (ou seu (s) empregador (es)) e Gazeta Médica 2023. Reutilização permitida de acordo com CC BY 4.0.

## RESUMO

Nicho uterino é um recesso localizado na parede anterior do istmo uterino, sobre a cicatriz de cesariana. Frequentemente esta condição é assintomática, mas pode estar associada a sintomas como hemorragia uterina anômala, dor pélvica e infertilidade secundária. A ecografia endovaginal é o método diagnóstico de primeira linha. O tratamento inclui métodos hormonais ou cirurgia, sendo que o tratamento cirúrgico parece ser o mais eficaz na resolução dos sintomas. Descrevemos o caso de uma mulher de 37 anos, com antecedentes obstétricos de uma gestação com parto por cesariana que apresentava queixas de dor pélvica e irregularidade menstrual. Foi solicitada ecografia endovaginal que relatou a presença de uma "...formação ovalada ecogénica de limites bem definidos com 28x17 mm na topografia da cicatriz de cesariana." Após discussão clínica com médico especialista em Ginecologia, a doente foi encaminhada para consulta hospitalar desta especialidade para investigação, tendo sido confirmado o diagnóstico de nicho uterino e cujo tratamento consistiu na colocação de sistema intrauterino.

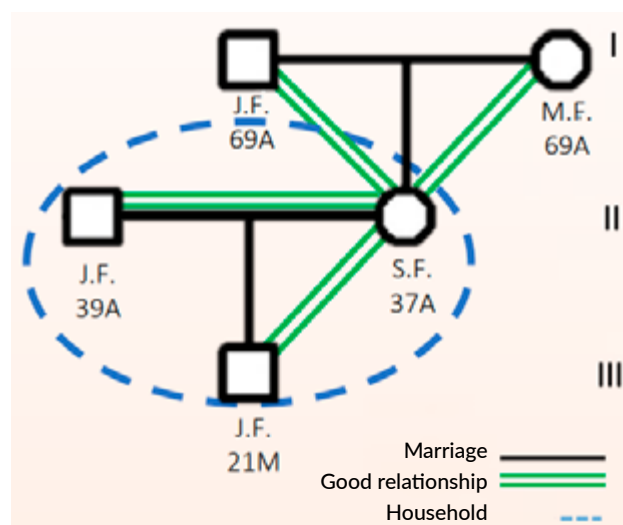
**PALAVRAS-CHAVE:** Cesariana/efeitos adversos; Cicatriz; Doenças Uterinas

## INTRODUCTION

The uterine niche, also called isthmocele, is a recess located in the anterior wall of the uterine isthmus, over the cesarean section scar.<sup>1</sup> This condition is often asymptomatic but may be associated with gynecological symptoms such as abnormal uterine bleeding, pelvic pain and secondary infertility.<sup>2</sup> Being an entity still little known, its diagnosis is often not made, and these symptoms end up being attributed to an unknown etiology. Its formation is attributed to a post-cesarean gynecological sequel, and taking into account that this surgical procedure has been increasingly frequent in clinical practice,<sup>3</sup> it is essential to be alert to this entity. The diagnostic process begins with the symptomatic evaluation followed by the necessary complementary diagnostic methods. Endovaginal ultrasound is the first-line diagnostic method.<sup>4</sup> Other methods may be used, such as hysteroscopy and magnetic resonance imaging.<sup>4</sup> Once the diagnosis has been established, it is essential to adapt the treatment to be applied on a case-by-case basis.<sup>5</sup> This treatment may include hormonal methods or surgery to remove the uterine recess, and surgical treatment seems to be the most effective in resolving symptoms.<sup>1</sup>

## CASE REPORT

A 37-year-old Caucasian woman. No relevant personal history, no usual medication. Non-smoker, she practices regular exercise, daily walks and yoga twice a week. Their food is based on the Mediterranean diet, with alcohol consumption only socially. Her obstetric history is characterized by a pregnancy and a cesarean delivery at the age of 36 (Fig. 1).



**FIGURE 1.** Representative genogram of the family in the case described.

After delivery, the user was observed in the context of a postpartum review consultation at her reference Health Center. At the time of consultation, the user had no loss of lochia and contraception was started with desogestrel 0.075 mg.

Four months later, in a Family Planning consultation at her reference health centre, the user reported complaints of menstrual irregularity and pelvic pain, which she associated with the start of taking oral contraception. In this consultation, an endovaginal ultrasound was requested to clarify the symptoms and its suspension was advised, using a condom as a contraceptive method until the result of this complementary examination was evaluated. Endovaginal ultrasound revealed "...along the anterior contour of the isthmus, an echogenic oval formation with well-defined limits measuring 28x17 mm axes, with a plane of cleavage with the uterus, in the topography of the cesarean scar.

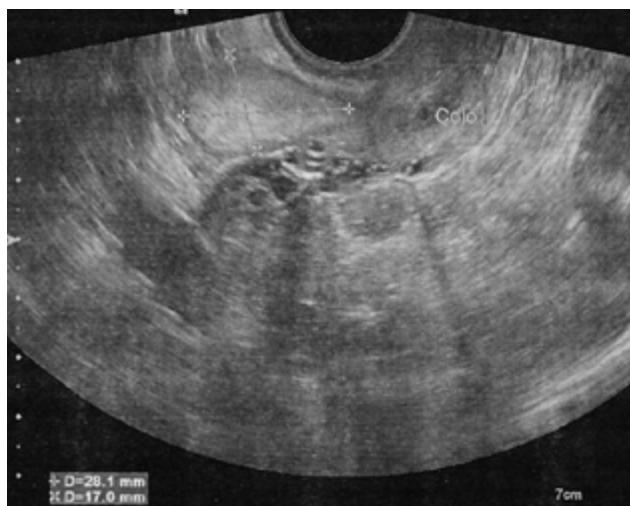
Ultrasound reassessment was recommended within 4 to 6 months or eventually for better characterization with magnetic resonance imaging". The image corresponding to this ultrasound is shown in Fig. 2.

Taking into account the recommendation made and the persistence of the complaints, a new ultrasound was performed 6 months later. In a scheduled consultation, the user also reported complaints of pelvic pain, very discreet, like "pricks", but without significant interference in her daily life. At the time of the consultation, she revealed that she had no intention of becoming pregnant, despite putting this hypothesis in the long term. The result of the new ultrasound was evaluated, which showed "...in the topography of the cesarean scar, the predominantly echogenic oval formation, already identified, dimensionally and morphologically stable." At this point, in order to improve the symptoms presented by the user, it was necessary to review contraception. After discussing the possible options and addressing the pros and cons of the various contraceptive methods, the user ended up choosing to start using a vaginal ring.

The present clinical case was discussed with a specialist in Gynecology, who hypothesized the diagnosis of a uterine niche and advised referral to a specialist consultation, a request that was made, with referral to the reference hospital.

In an outpatient Gynecology consultation, which took place about 6 months after the referral by the family physician, the user continued to complain of menstrual irregularities, no longer associated with pain, whose onset was reported in the postpartum period.

The gynecological examination showed no significant alterations and the endovaginal ultrasound performed



**FIGURE 2.** Endovaginal ultrasound image identifying uterine niche.

at the time of consultation was superimposed on those performed previously. After discussing the possible contraceptive methods to be applied in this situation, it ended up being decided to place an intrauterine system with levonorgestrel, which it maintains to date.

About two months after the Gynecology consultation, the user was reassessed in a scheduled consultation at her reference health centre. She was well-adapted to the new contraceptive method, with no complaints of pain or vaginal bleeding. Still without a decision regarding the possible future pregnancy. She referred to a very significant improvement in her quality of life and was really satisfied with the solution found, despite having been two difficult years, due to the symptoms she was reporting. Her sexual activity had improved significantly, with no reported pain complaints.

## DISCUSSION

The recognition of the uterine niche is essential, since the rate of cesarean sections has been increasing, and consequently its possible complications. Pelvic pain and menstrual irregularities are common postpartum symptoms being evaluated in primary health care. It is important to understand the cause of these complaints for efficient therapeutic guidance. The uterine niche can be surgically resected via operative hysteroscopy, vaginal surgery, laparotomy/laparoscopy, or a combined approach. Hormonal contraception (oral or IUS) can be an effective alternative to treat the symptoms.

## DECLARAÇÃO DE CONTRIBUIÇÃO /CONTRIBUTORSHIP STATEMENT

FM: Development and writing of the article

JB, FA, JS, JTS AND JA: Development and review the article

All authors approved the final version

FM: Elaboração e escrita do artigo

JB, FA, JS, JTS E JA: Elaboração e revisão do artigo

Todos os autores aprovaram a versão final

## RESPONSABILIDADES ÉTICAS

**CONFLITOS DE INTERESSE:** Os autores declaram a inexistência de conflitos de interesse na realização do presente trabalho.

**FONTES DE FINANCIAMENTO:** Não existiram fontes externas de financiamento para a realização deste artigo.

**CONFIDENCIALIDADE DOS DADOS:** Os autores declaram ter seguido os protocolos da sua instituição acerca da publicação dos dados de doentes.

**CONSENTIMENTO:** Consentimento do doente para publicação obtido.

**PROVENIÊNCIA E REVISÃO POR PARES:** Não comissionado; revisão externa por pares.

## ETHICAL DISCLOSURES

**CONFLICTS OF INTEREST:** The authors have no conflicts of interest to declare.

**FINANCING SUPPORT:** This work has not received any contribution, grant or scholarship.

**CONFIDENTIALITY OF DATA:** The authors declare that they have followed the protocols of their work center on the publication of data from patients.

**PATIENT CONSENT:** Consent for publication was obtained.

**PROVENANCE AND PEER REVIEW:** Not commissioned; externally peer reviewed.

## REFERENCES

1. Subtil S, Carvalho MJ, Carvalho G, Almedia e Sousa L Águas F. Nicho uterino: implicações em ginecologia. *Acta Obstet Gynecol Port* [Internet]. 2019; Disponível em: [http://scielo.pt/scielo.php?script=sci\\_arttext&pid=S164658302019000100006&lng=pt](http://scielo.pt/scielo.php?script=sci_arttext&pid=S164658302019000100006&lng=pt).
2. Kremer TG, Ghiorzi IB, Dibi RP. Isthmocele: An overview of diagnosis and treatment. *Rev Assoc Med Brasil*. 2019;65:714-21. doi:10.1590/1806-9282.65.5.714.
3. Kulshrestha V, Agarwal N, Kachhawa G. Post-caesarean Niche (Isthmocele) in Uterine Scar: An Update. *J Obstet Gynaecol India*. 2020;70:440-6. doi: 10.1007/s13224-020-01370-0.
4. Budny-Winska J, Pomorski M. Uterine niche after cesarean section: a review of diagnostic methods. *Ginekol Pol*. 2021;92:726-30. doi: 10.5603/GP.a2021.0195.
5. Tanos V, Toney ZA. Uterine scar rupture - Prediction, prevention, diagnosis, and management. *Best Pract Res Clin Obstet Gynaecol*. 2019;59:115-31. doi: 10.1016/j.bpobgyn.2019.01.009.